



# Corneal collagen crosslinking with riboflavin and ultraviolet-A light in progressive keratoconus: Ten-year results

Frederik Raiskup, MD, PhD, FEBO, Anja Theuring, MD, Lutz E. Pillunat, MD, Eberhard Spoerl, PhD

**PURPOSE:** To analyze the 10-year results of corneal collagen crosslinking (CXL) for keratoconus.

**SETTING:** Department of Ophthalmology, University Hospital, Dresden, Germany.

**DESIGN:** Retrospective interventional case series.

**METHODS:** The study included eyes treated for progressive keratoconus from 2000 to 2004. Corneal collagen crosslinking was performed by applying riboflavin and ultraviolet-A. The corrected distance visual acuity (CDVA), corneal topography, and endothelial cell count (ECC) were recorded preoperatively and 10 years postoperatively.

**RESULTS:** The study enrolled 24 patients (34 eyes). The mean age of the 18 men and 6 women was 28.4 years  $\pm$  7.3 (SD) and the mean follow-up, 131.9  $\pm$  20.1 months. The mean apical keratometry (K) value was 61.5 diopters (D) preoperatively and 55.3 D 10 years postoperatively; the decrease was statistically significant ( $P < .001$ ). The mean values for maximum K (53.2 D and 49.56 D, respectively) and minimum K (47.5 D and 45.5 D, respectively) were also significantly lower ( $P < .001$ ). The preoperative and postoperative CDVA were statistically significantly different ( $P = .002$ ). The mean CDVA improved by 0.14 logMAR over preoperatively; the change was statistically significant ( $P = .002$ ). The ECC was unchanged.

**CONCLUSIONS:** Corneal CXL was effective in treating progressive keratoconus, achieving long-term stabilization of the condition. It was easy to perform, had a good safety profile, and reduced the need for corneal transplantation.

**Financial Disclosure:** No author has a financial or proprietary interest in any material or method mentioned.

*J Cataract Refract Surg* 2015; 41:41–46 © 2015 ASCRS and ESCRS

Keratoconus is a noninflammatory degenerative eye condition in which the cornea progressively loses stability. The loss of stability leads to protrusion and a subsequent increase in stromal thinning. The condition results in an irregular corneal astigmatism and severe myopia,<sup>1</sup> which lead to progressive impairment of vision. Both eyes are commonly affected; however, keratoconus manifests asymmetrically.<sup>2</sup> Because it initially manifests at a young age, it has a considerable impact on a patient's quality of life and life planning. The prevalence of keratoconus varies considerably according to ethnic and regional factors, ranging from 50 and 600 in 100 000 individuals in the general

population; its incidence rate is 1 to 2 in 100 000 individuals.<sup>3</sup>

The progression of keratoconus is extremely variable, and the stage of disease influences the treatment strategy. In the early stages, the first choice for therapy is correction of the irregular astigmatism with hard contact lenses. For eyes with contact lens intolerance, implantation of intrastromal corneal ring segments might be the next step in the treatment. In cases involving very severe irregular astigmatism or corneas with dense stromal scars, the next therapeutic option is deep anterior lamellar keratoplasty or a penetrating corneal graft.<sup>4</sup>

Corneal collagen crosslinking (CXL) is an internationally recognized regimen for the treatment of progressive keratoconus. This procedure can delay or halt further progression of keratoconus and can reduce the need for lamellar or perforating penetrating keratoplasty (PKP).

In CXL, a riboflavin (vitamin B<sub>2</sub>) solution undergoes a photochemical reaction in the presence of ultraviolet-A (UVA) light in the corneal stroma, forming free oxygen radicals. In animal experiments,<sup>5,6</sup> crosslinked corneas examined using confocal microscopy showed evidence of considerably more crosslinking in the collagen structure than the corneas without CXL. The photochemical reaction causes the collagen to form additional covalent connections between its fibers, which stabilizes the stromal collagen fibers, improving the collagen's structure.

The aim of our study was to identify the long-term effects, safety, and side effects of CXL performed according to the classic Dresden protocol.

## PATIENTS AND METHODS

This retrospective nonrandomized study comprised patients with progressive keratoconus. Corneal CXL was indicated in all patients based on the progression rate of the condition (ie, an increase in the apical keratometry [K] value of the corneal topography of at least 1.0 diopter [D] within the 6 to 12 months before treatment). The treatment was performed in an outpatient clinic using a previously described procedure.<sup>7,8</sup> The study was approved by the local institutional review board and adhered to the tenets of the Declaration of Helsinki. All patients provided written informed consent.

Preoperative and 10-year postoperative examinations included measurement for corneal thickness (Pachette ultrasonic pachymeter, Technomed GmbH, and Pentacam HR, Oculus Optikgeräte GmbH, respectively); corneal curvature (maximum K, minimum K, apical K); corneal astigmatism from the topography in the central 3.0 mm zone (C-Scan videokeratoscope, Technomed GmbH, and Pentacam HR, respectively); and logMAR corrected distance visual acuity (CDVA) with glasses. In addition, a slitlamp examination and an endothelial cell count (ECC) were performed

(EM-1200 endothelial cell microscope, Tomey Corp., and specular microscope CEM-530, Nidek Co., Ltd., respectively). Retreatment of an ectatic cornea was indicated if the apical K value increased at least 1.0 D over 2 consecutive follow-up visits compared with its value during the steady-state period after the first treatment. Contact lens wearers were instructed to discontinue their use 2 weeks before the examination to avoid warpage and false K values.

Statistical analysis was performed with linear mixed models with repeated measures, using SPSS software (version 21, SPSS GmbH).

## RESULTS

This study analyzed 34 eyes (24 patients) over a mean follow-up of 10.9 years  $\pm$  1.7 (SD). Keratoconus commonly presents during puberty or early adulthood; this was reflected in the patient cohort. The mean patient age at the time of the procedure was 28.4  $\pm$  7.3 years (range 14 to 42 years). Keratoconus is more common in men than women; the current study involved a significantly greater proportion of men (75.0%) than women (25.0%). At treatment, 5 eyes (14.7%) were in an advanced stage of keratoconus and showing secondary signs, specifically corneal scarring. However, the CDVA in these eyes remained good.

The maximum K, minimum K, and K value at the apex of the keratoconus were significantly lower 10 years after treatment (Figure 1). The mean astigmatism was also significantly reduced, from 5.7 D (95% confidence interval [CI], 4.4-7.0) to 4.0 D (95% CI, 2.9-5.1) (Figure 2). However, 2 eyes required repeat CXL, 1 after 5 years and 1 after 10 years. In 1 case, the K values increased and visual acuity worsened. In the other, the K values increased, despite an initial improvement in visual acuity.

The mean CDVA also significantly improved, by 0.14 logMAR ( $P=.002$ ) (Figure 3). The preoperative mean CDVA was 0.40 logMAR (95% CI, 0.30-0.49) and the 10-year postoperative CDVA was 0.26 logMAR (95% CI, 0.19-0.33). In 10 eyes (29.4%), the preoperative CDVA was measured after correction by hard contact lenses. These study participants continued to use contact lenses postoperatively and tended to have better postoperative CDVA when wearing contact lenses than when wearing glasses (Figure 4).

Relevant complications, such as prolonged reepithelialization, infection, limbal stem cell insufficiency, and endothelial decompensation, were not observed during the 10-year follow-up. However, 1 eye (2.9%) developed a permanent stromal corneal scar that limited visual acuity postoperatively. Predisposing factors, such as very high preoperative K values and a thinner cornea, were not present in this patient. In addition, the anterior stroma in 13 eyes (38.2%) showed a persistent haze at the 10-year follow-up, although this did not affect the CDVA.

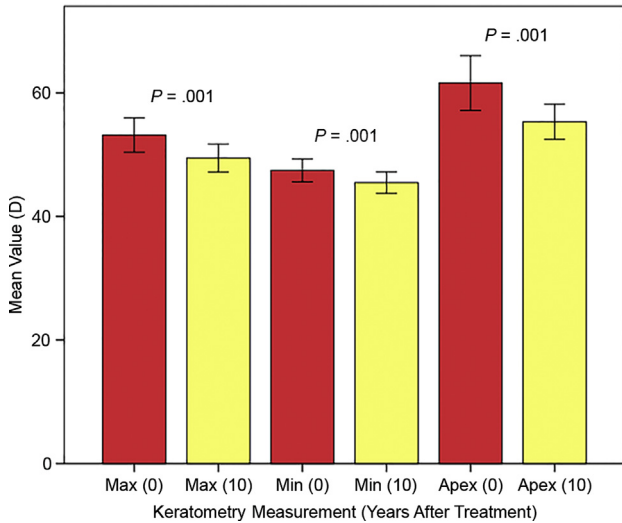
Submitted: July 16, 2014.

Final revision submitted: September 3, 2014.

Accepted: September 28, 2014.

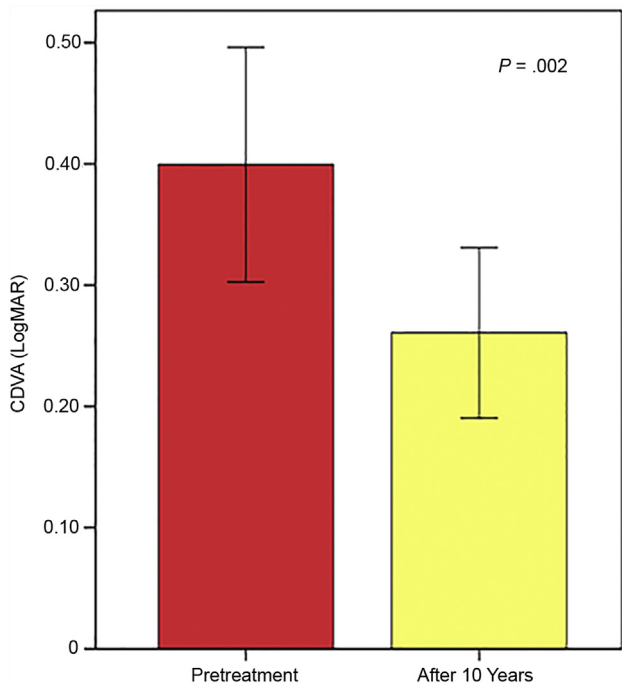
From the Department of Ophthalmology (Raiskup, Theuring, Pillunat, Spoerl), C.G. Carus University Hospital, Dresden, Germany; the Department of Ophthalmology (Raiskup), Faculty of Medicine Hradec Králové, Charles University, Prague, Czech Republic.

Corresponding author: Frederik Raiskup, MD, PhD, FEBO, Department of Ophthalmology, C.G. Carus University Hospital, Fetscherstrasse 74, 013 07 Dresden, Germany. E-mail: [frederik.raiskup@uniklinikum-dresden.de](mailto:frederik.raiskup@uniklinikum-dresden.de).

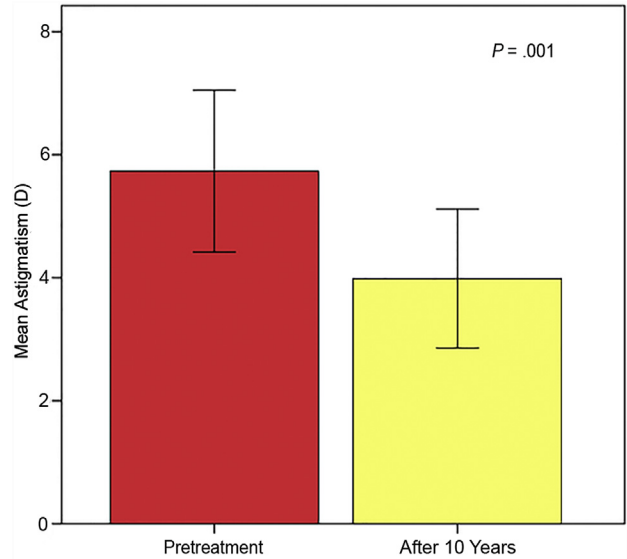


**Figure 1.** Mean K values before and 10 years after CXL (apex = the apex of the keratoconus; max = maximum; min = minimum).

Collagen crosslinking did not cause long-term endothelial cell deterioration. There were no clinical signs of endothelial decompensation at any time point. The mean ECC before treatment was 2214 cells/mm<sup>2</sup>; however, eyes had a higher ECC (2831 cells/mm<sup>2</sup>) postoperatively.



**Figure 3.** The CDVA before and 10 years after CXL.

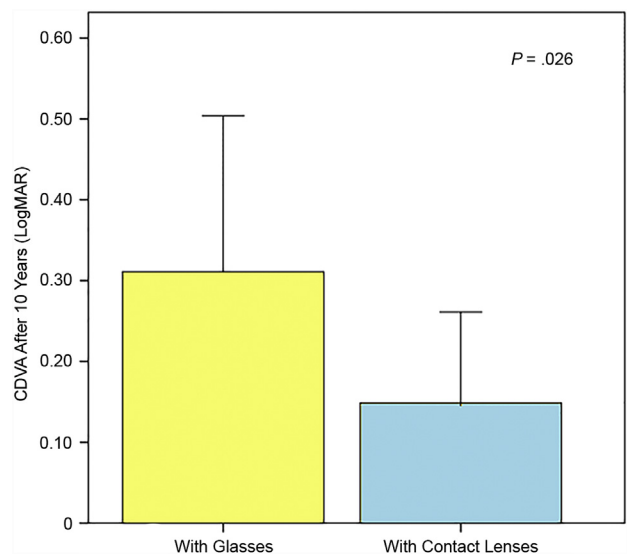


**Figure 2.** Mean astigmatism before and 10 years after CXL.

## DISCUSSION

Early in the course of keratoconus, glasses or soft contact lenses might correct vision adequately; however, as the disease progresses, rigid gas-permeable contact lenses become the preferred treatment. In 2004, keratoconus accounted for 15.1% of the more than 30 000 corneal transplantations performed in the United States.<sup>9</sup>

Penetrating keratoplasty is by far the most common human-tissue transplantation procedure worldwide. Data from the Australian Corneal Graft Registry, one



**Figure 4.** The CDVA in 10 eyes corrected with glasses and hard contact lenses 10 years after CXL.

of the largest graft registries, show a 91% successful graft rate 1 year postsurgery and a 74% success rate at 5 years for all diagnoses that are normally indicated for corneal graft. The success of corneal transplantation has been attributed to advances in microsurgical techniques, eye banking, corneal preservation, and surgeons' ability to detect and treat postoperative complications.<sup>10</sup>

Nevertheless, many patients with successful (clear) corneal grafts might have poor visual function postoperatively because of irregular astigmatism or other complications. Surgeons usually evaluate the results of PKP using conventional measures such as Snellen visual acuity, graft clarity, and keratometry. Although these tests are helpful for measuring important indices associated with visual function, they do not always correlate precisely with a patient's ability to perform activities of daily living. The surgeon's definition of a successful corneal graft might not accurately reflect a patient's perception of success because despite achieving a good CDVA and a clear graft, some patients report dissatisfaction with their vision and limitations in daily functioning. These findings often are attributable to differences in expectations (realistic or not), inadequate preoperative counseling, and/or limits in the patient's adaptation abilities.<sup>10</sup>

The lifetime economic burden on patients with keratoconus is not negligible. Over an average disease duration of 37 years, treating an individual for keratoconus in the U.S. costs \$24 168 more than treating an individual for myopia (using an estimated cost above that for routine vision care). More than one half of this is the expected cost of a corneal graft and treatment of the related postsurgical complications. Moreover, the expected cost of regular ophthalmologic or optometric care (regular visits and nonsurgical treatment) in the U.S. is 42.3% of the total cost of care (regular care and surgical treatment).<sup>11</sup>

Because keratoconus usually manifests in young adults, refractive errors within the younger age group should be taken into consideration; the annual cost of refractive care for all young adults in the U.S. amounts to \$3.6 billion. The average annual cost for individual routine vision care is \$200, but for patients with keratoconus, it is \$653.<sup>11</sup> Putting these costs in the context of the economic impact of other diseases involving visual impairment, in the U.S., the estimated economic impact of major adult visual disorders such as age-related macular degeneration, cataracts, diabetic retinopathy, glaucoma, and refractive error was \$51.4 billion in 2007.<sup>12</sup>

Corneal collagen crosslinking is a minimally invasive treatment option for preventing the progression of keratoconus. For more than 10 years, we have used CXL in our clinic. A pilot clinical study in 2003

by Wollensak et al.<sup>7</sup> showed the first indication of the treatment's efficacy.

The results in our study indicate that CXL can achieve long-term (10 years) disease stabilization in eyes of patients with progressive keratoconus. The CXL treatment significantly reduced the maximum and minimum corneal curvatures and the curvature at the apex of the keratoconus in the eyes in our study population. The CDVA also significantly improved by 0.14 logMAR, which can be attributed to the reductions in corneal astigmatism and corneal distortion and to a better fit of the hard contact lenses enabled by the regularization of the corneal surface. These findings confirm the reported outcomes in a larger case series,<sup>8</sup> which observed 241 eyes of keratoconus patients for between 3 and 6 years. In that uncontrolled retrospective study, a statistically significant improvement was also observed in corneal astigmatism, CDVA, and maximum K.

In our study, only 2 patients required the CXL to be repeated because of further progression of the disease, 1 after 5 years and 1 after 10 years. Both cases subsequently showed stabilization of the reported corneal topographic K values. A maximum K value of more than 58.0 D and a thinner cornea at the time of the procedure were predisposing factors in both cases.<sup>13,14</sup>

The limitations of our study include the design (retrospective, nonrandomized, and without a control group) and the small number of cases. In addition, because it analyzed eyes rather than patients, patient-specific aspects were potential sources of error.

There are restrictions to consider in determining whether CXL is indicated. Unless the corneal thickness is at least 400  $\mu\text{m}$  after the epithelium is removed during the standard treatment protocol, the corneal endothelium could be damaged. In addition, insufficient absorption of the energy-rich UVA light and an excessively high concentration of free oxygen radicals in the deeper corneal layers cause a toxic effect.<sup>15</sup> In this study, the mean corneal thickness at surgery was  $488 \pm 46 \mu\text{m}$ , which fulfilled the treatment criteria. In line with expectations, CXL had no effect on the endothelial cells as of the 10-year follow-up. However, because of the retrospective design of the study, an ECC was not available for all eyes at the start of the data collection. Statistical analysis of patients whose eyes were examined preoperatively and 10 years postoperatively showed a stable or significantly higher ECC at 10 years than preoperatively. Because an increase in endothelial cells is unlikely over time, the difference is most likely attributable to changes in the measurement device used. Wittig et al.<sup>16</sup> also report no statistically significant difference in the ECC 3 years after CXL in a prospective randomized study; the ECC



loss rate was 1.40% in 3 years. In the published literature, the annual physiologic loss of endothelial cells in healthy corneas and in corneas with early-stage Fuchs corneal endothelial dystrophy is 0.44% to 0.60%.<sup>17-19</sup> Extrapolated over 10 years, our results and those from Wittig et al.<sup>16</sup> indicate a physiologic endothelial cell loss of 6.0% or less. The endothelial cell loss rate after CXL in our study is also comparable to the endothelial cell loss after laser in situ keratomileusis (LASIK)<sup>20</sup> or photorefractive keratectomy (PRK).<sup>21</sup> Kato et al.<sup>20</sup> report an endothelial cell loss of 1.20% after 5 years for LASIK, and Isager et al. report a 1.6% endothelial cell loss after a 4-year follow-up for PRK.

Because of the potential for postsurgery complications, CXL should be performed only if there is solid evidence of disease progression. However, few complications have been reported and they could be temporary, such as wound-healing problems, infectious keratitis, or noninfectious keratitis,<sup>22</sup> or permanent, such as corneal scarring with irreversible vision reduction. Severe complications, such as corneal melting and perforation, are also possible. In the present study, only 1 eye (2.9%) had postoperative vision-limiting stromal scarring. Consistent with this finding are the results of Koller et al.,<sup>13</sup> who examined 117 participants 12 months after CXL was performed. They found permanent corneal scarring in 2.8% of cases. In a study<sup>23</sup> of the CXL treatment and 12-month follow-up of 163 eyes, a slightly higher proportion of eyes had persistent vision-impairing deep stromal scarring (8.6%). That study also reported an overall increased risk for scarring in eyes having very high preoperative apical K values for the keratoconus and in eyes with thinner corneas, as typically seen in an advanced stage of keratoconus.

Keratoconus patients have the best prognosis after corneal transplantation<sup>10</sup>; however, corneal transplantation might not be the best treatment option because patients with this condition are often young and very active in their work and leisure activities. In addition, their life planning is frequently not yet complete, particularly with respect to their careers. Operative treatment, especially corneal transplantation, is an elaborate, time-intensive, and expensive procedure and it places a large burden on the affected individuals. Considering the limited lifespan for transplantation and its possible complications such as rejection or transplant failure, CXL treatment is a promising therapeutic alternative. Corneal collagen crosslinking offers clinical, economic, and psychosocial advantages<sup>8</sup>: It is associated with fewer complications, can be performed on an outpatient basis, is minimally invasive, and is relatively inexpensive.

### WHAT WAS KNOWN

- The standard CXL procedure after epithelial removal is safe and effective for treating progressive keratoconus.
- Short- and medium-term results show stable ectasia and a low occurrence of serious posttreatment complications after CXL treatment.

### WHAT THIS PAPER ADDS

- Long-term (10-year) results confirm previous findings regarding CXL's ability to stabilize keratoconus, reduce the central corneal curvature, and improve CDVA.
- Long-term postoperative side effects generally and corneal scarring in particular occurred in cases with predisposing factors only.
- Corneal collagen crosslinking can be repeated safely, with effective results.

### REFERENCES

1. Grünauer-Kloevekorn C, Duncker GIW. Keratokonus: epidemiologie, Risikofaktoren und Diagnostik [Keratoconus: epidemiology, risk factors and diagnosis]. *Klin Monatsbl Augenheilkd* 2006; 223:493–502
2. Zadnik K, Barr JT, Edrington TB, Everett DF, Jameson M, McMahon TT, Shin JA, Sterling JL, Wagner H, Gordon MO; the Collaborative Longitudinal Evaluation of Keratoconus (CLEK) Study Group. Baseline findings in the Collaborative Longitudinal Evaluation of Keratoconus (CLEK) Study. *Invest Ophthalmol Vis Sci* 1998; 39:2537–2546. Available at: <http://www.iovs.org/content/39/13/2537.full.pdf>. Accessed October 1, 2014
3. Kennedy RH, Bourne WM, Dyer JA. A 48-year clinical and epidemiologic study of keratoconus. *Am J Ophthalmol* 1986; 101:267–273
4. Goebels S, Seitz B, Langenbacher A. Diagnostik und stadien-gerechte Therapie des Keratokonus; Eine Einführung in das Homburger Keratokonuscenter (HKC) [Diagnostics and stage-oriented therapy of keratoconus; introduction to the Homburg keratoconus center (HKC)]. *Ophthalmologie* 2013; 110:808–809
5. Spoerl E, Huhle M, Seiler T. Induction of cross-links in corneal tissue. *Exp Eye Res* 1998; 66:97–103
6. Wollensak G, Spoerl E, Seiler T. Stress-strain measurements of human and porcine corneas after riboflavin-ultraviolet-A-induced cross-linking. *J Cataract Refract Surg* 2003; 29:1780–1785
7. Wollensak G, Spoerl E, Seiler T. Riboflavin/ultraviolet-A-induced collagen crosslinking for the treatment of keratoconus. *Am J Ophthalmol* 2003; 135:620–627. Available at: [http://grmc.ca/assets/files/collagen\\_crosslinking\\_2003\\_wollensak.pdf](http://grmc.ca/assets/files/collagen_crosslinking_2003_wollensak.pdf). Accessed October 1, 2014
8. Raiskup-Wolf F, Hoyer A, Spoerl E, Pillunat LE. Collagen crosslinking with riboflavin and ultraviolet-A light in keratoconus: long-term results. *J Cataract Refract Surg* 2008; 34:796–801
9. Eye Bank Association of America. Statistical Report on Eye Banking Activity for 2004. Washington, DC, Eye Bank Association of America, 2005

10. Mendes F, Schaumberg DA, Navon S, Steinert R, Sugar J, Holland EJ, Dana MR. Assessment of visual function after corneal transplantation: the Quality of Life and Psychometric Assessment After Corneal Transplantation (Q-PACT) Study. *Am J Ophthalmol* 2003; 135:785–793
11. Rebenitsch RL, Kymes SM, Walline JJ, Gordon MA. The lifetime economic burden of keratoconus: a decision analysis using a Markov model. *Am J Ophthalmol* 2011; 151:768–773
12. Rein DB, Zhang P, Wirth KE, Lee PP, Hoerger TJ, McCall N, Klein R, Tielsch JM, Vijan S, Saaddine J. The economic burden of major adult visual disorders in the United States. *Arch Ophthalmol* 2006; 124:1754–1760. correction 2007; 125:1304. Available at: [http://archophth.jamanetwork.com/data/Journals/OPHTH/9977/ese60005\\_1754\\_1760.pdf](http://archophth.jamanetwork.com/data/Journals/OPHTH/9977/ese60005_1754_1760.pdf). Correction available at: <http://archophth.jamanetwork.com/article.aspx?articleid=419804>. Both accessed October 1, 2014
13. Koller T, Mrochen M, Seiler T. Complication and failure rates after corneal crosslinking. *J Cataract Refract Surg* 2009; 35:1358–1362
14. Hafezi F. Limitation of collagen cross-linking with hypoosmolar riboflavin solution: failure in an extremely thin cornea. *Cornea* 2011; 30:917–919
15. Spoerl E, Hoyer A, Pillunat LE, Raiskup F. Corneal cross-linking and safety issues. *Open Ophthalmol J* 2011; 5:14–16. Available at: <http://www.ncbi.nlm.nih.gov/pmc/articles/PMC3052642/pdf/TOOPHTJ-5-14.pdf>. Accessed October 1, 2014
16. Wittig-Silva C, Chan E, Islam FMA, Wu T, Whiting M, Snibson GR. A randomized, controlled trial of corneal collagen cross-linking in progressive keratoconus: three-year results. *Ophthalmology* 2014; 121:812–821
17. Bourne WM, Nelson LR, Hodge DO. Central corneal endothelial cell changes over a ten-year period. *Invest Ophthalmol Vis Sci* 1997; 38:779–782. Available at: <http://www.iovs.org/cgi/reprint/38/3/779>. Accessed October 1, 2014
18. Hatou S, Shimmura S, Shimazaki J, Usui T, Amano S, Yokogawa H, Kobayashi A, Zheng X, Shiraishi A, Ohashi Y, Inatomi T, Tsubota K. Mathematical projection model of visual loss due to Fuchs corneal dystrophy. *Invest Ophthalmol Vis Sci* 2011; 52:7888–7893. Available at: <http://www.iovs.org/content/52/11/7888.full.pdf>. Accessed October 1, 2014
19. Murphy C, Alvarado J, Juster R, Maglio M. Prenatal and postnatal cellularity of the human corneal endothelium; a quantitative histologic study. *Invest Ophthalmol Vis Sci* 1984; 25:312–322. Available at: <http://www.iovs.org/cgi/reprint/25/3/312.pdf>. Accessed October 1, 2014
20. Kato N, Toda I, Hori-Komai Y, Sakai C, Tsubota K. Five-year outcome of LASIK for myopia. *Ophthalmology* 2008; 115:839–844.e2
21. Isager P, Guo S, Hjortdal JØ, Ehlers N. Endothelial cell loss after photorefractive keratectomy for myopia. *Acta Ophthalmol Scand* 1998; 76:304–307. Available at: <http://onlinelibrary.wiley.com/doi/10.1034/j.1600-0420.1998.760310.x/pdf>. Accessed October 1, 2014
22. Bödemann M, Kohnen T. Ulcus corneae durch MRSA nach UV/Riboflavin-Crosslinking bei Keratokonus [Corneal ulcer caused by MRSA after UV/riboflavin cross-linking in a patient with bilateral keratoconus]. *Ophthalmologie* 2012; 109:1112–1114
23. Raiskup F, Hoyer A, Spoerl E. Permanent corneal haze after riboflavin-UVA-induced cross-linking in keratoconus. *J Refract Surg* 2009; 25:S824–S828



First author:  
 Frederik Raiskup, MD, PhD, FEBO  
*Department of Ophthalmology,  
 C.G. Carus University Hospital,  
 Dresden, Germany*